

Cephalometric analysis of changes in occlusal relationship

Demetrios J. Halazonetis

Private practice, Athens, Greece

SUMMARY One of the main problems in assessing the mode of action of various treatment modalities is the method of measuring the treatment change. The purpose of the present study was to develop a cephalometric method that would permit a detailed evaluation of the individual growth processes (skeletal and dental) that contribute to the overall change in occlusal relationship. The change in molar relationship was resolved in five components, i.e. translation of the maxilla, of the upper molar, of the mandible, of the lower molar, and rotation of the mandible. These movements were recorded using regional superimposition of various structures, with the aid of a computer program. Derotation of the mandible was performed to remove any confounding effects of total mandibular rotation on the interpretation of the measurements. The results show that assessment of treatment effects can be carried out by comparison of the five resulting vectors.

Introduction

The orthodontic literature contains numerous studies that attempt to evaluate the skeletal and dental effects of various treatment modalities, especially those concerned with Class II correction. In such studies, the primary aim is to assess the contribution of the mandibular and maxillary skeletal and dental changes (growth or treatment induced) on the overall change of antero-posterior occlusal relationship. Unfortunately, the cephalometric analyses that are commonly used are those that have been developed for diagnosis and treatment planning, and may not be appropriate for this task.

In this study a cephalometric measurement system is proposed, specifically developed for analysing the contribution of underlying skeletal and dental changes on the change in molar relationship. The development and acceptance of such a system could permit a better understanding of the effects of treatment methods.

The basic outline of the method is presented first in order to familiarize the reader with the measurements, following which the principles on which the method was based are explained.

Outline of the method

The proposed method is applied on two lateral cephalograms of the same patient, taken with a time interval between them, and referred to here as Initial and Final. The method concentrates on the change in position of the upper and lower first molars relative to the cranial base. It consists of the following steps:

1. The initial position of the molars is transferred and marked on the final radiograph, after structural superimposition of the two radiographs on the anterior cranial base (Figures 1a and 2a).
2. An intermediary position of the upper molar is marked on the final radiograph. This is obtained by superimposing the radiographs on internal stable structures of the maxilla and transferring the initial molar to the final radiograph (Figure 1b).
3. A vector is drawn between the initial upper molar and the intermediary position, and is named *Maxillary Skeletal*. This vector represents the displacement of the molar due to skeletal displacement of the maxilla relative

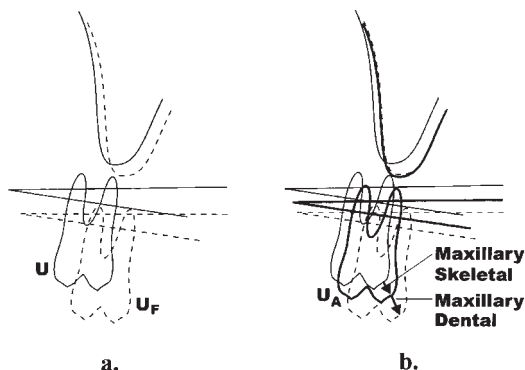


Figure 1 (a) Initial and final radiographs superimposed on the cranial base (structural superimposition). Continuous line: Initial. Broken line: Final. (b) Intermediary position (U_A) of molar obtained by structural superimposition of the maxilla (here on the anterior and posterior surfaces of the zygomatic process).

to the cranial base. A vector is also drawn between the intermediary and final positions, and is named *Maxillary Dental*, this being due to dental movement of the molar relative to the maxilla. These two vectors constitute the measurements for the upper molar.

The measurements related to the lower molar are three and are obtained by the following steps:

4. The mandibular total rotation is measured by performing a structural superimposition on the mandible, and measuring the angle between the cranial base on the initial and final cephalogram. The measured total rotation is used in step 6 below.
5. The initial and final cephalogram are superimposed on internal structures of the mandible and the initial lower molar is transferred to the final radiograph. This position of the lower molar is termed L_A (Figure 2b).
6. Position L_A and the final position of the lower molar (L_F) are copied on acetate paper, which is placed on the final radiograph. The acetate paper is then rotated by an angle equal, but opposite to the previously measured total rotation, using the centre of the condyle as the rotation centre (Figure 2c).

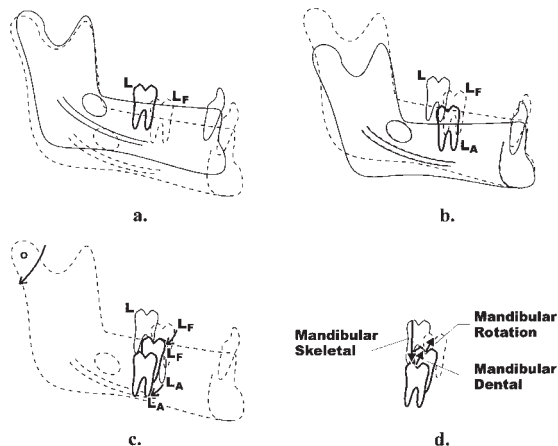


Figure 2 (a) Structural superimposition on the cranial base. Initial molar (L) copied on final radiograph. (b) Superimposition on internal stable structures of the mandible. Initial molar copied on final radiograph (L_A). (c) Molars L_F and L_A copied on acetate paper and rotated around condyle by an amount equal but opposite to the measured total rotation. (d) Mandibular vectors: *Mandibular Skeletal* measured between initial molar (L) and rotated L_A on acetate paper. *Mandibular Dental* measured between rotated L_A and rotated L_F (both on acetate paper). *Mandibular Rotation* measured between rotated L_F on acetate paper and L_F on radiograph.

7. The following vectors are drawn, which constitute the measurements for the lower molar: *Mandibular Skeletal*, from the initial molar position L to position L_A on the rotated acetate paper; *Mandibular Dental*, from position L_A on the acetate paper to position L_F on the acetate paper; *Mandibular Rotation*, from position L_F on the acetate paper to position L_F on the final radiograph (Figure 2d).
8. The two vectors for the upper molar and the three vectors for the lower molar are drawn separately, orientated to the occlusal plane, to obtain a graphical presentation of the measurements (Figure 3).

In practice the method is performed differently than described above in order to avoid sources of potential error and to reduce the necessary time and labour. A detailed description is presented in the Appendix.

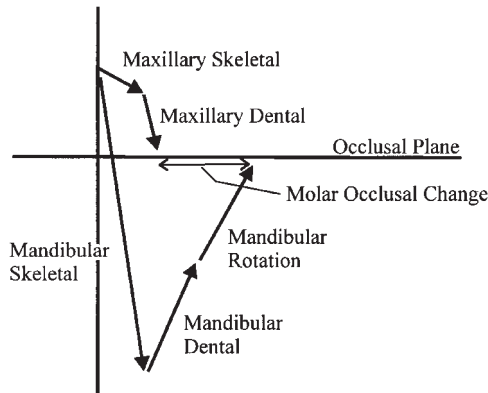


Figure 3 Graphical presentation of the measurements. The horizontal axis represents the final occlusal plane. Vectors *Mandibular Skeletal* and *Maxillary Skeletal* have been positioned to start from the same point. The other vectors are drawn end-to-end to these.

Justification and explanation of the method

Upper molar

The main growth processes that contribute to the total displacement of the upper molar are considered to be: (a) the skeletal relocation of the maxilla relative to the cranial base; and (b) the dental movement of the molar relative to the maxilla. The skeletal component is due to primary and secondary displacement (Enlow, 1982) of the maxilla from the cranial base. To assess this displacement, the structural superimposition of step 2 described above is performed. External anatomical points of the maxilla (e.g. point A, ANS, PNS) are not used, because such points are not stable during growth, they depend on local surface remodelling processes and may lead to erroneous conclusions regarding maxillary growth (Baumrind *et al.*, 1987). The ideal situation would be to perform a superimposition on metallic implants. However, since these are seldom available, superimposition on the anterior and posterior surface of the zygomatic process may be used, or any other structural superimposition that proves to be comparable to metallic implants (Björk and Skieller, 1977; Nielsen, 1989; Doppel *et al.*, 1994).

The purpose of the structural superimposition of the maxilla is to establish the intermediary

position U_A of the upper molar by transferring the initial molar to the final cephalogram. This would be the final position of the upper molar if no dental movement of the molar had occurred (e.g. if the molar were ankylosed to the surrounding bone). Therefore, the displacement of the molar from the initial position to the intermediary position represents a pure skeletal effect, while the displacement from the intermediary to the final position is due solely to dental movement. It is, of course, recognized that these movements take place concurrently during growth and treatment, and the upper molar probably never passes through point U_A . The vector measurements described in step 3 are merely mathematical representations of the skeletal and dental components which, when added together, give the total molar displacement.

Lower molar

The lower molar changes position due to: (a) the combined growth of the mandibular condyle and the relocation of the fossa; (b) the dental movement of the molar relative to the mandible; and (c) the effect of mandibular rotation.

The placement of metallic implants in the corpus of the mandible has shown that the internal structures of the mandible may rotate relative to the cranial base during growth (Björk and Skieller, 1972, 1983). This rotation was termed *total rotation*. Total rotation is only evident when the mandible is superimposed on metallic implants or stable internal anatomic structures. Superimposition along the borders of the mandible will not reveal total rotation, because extensive compensatory periosteal remodelling masks it to a large extent. Total rotation is directly related to the amount and direction of condylar growth and to the vertical development of the dentition. Large condylar growth in an anterior direction, accompanied by small vertical alveolar growth is expected to result in a large anterior total rotation. Conversely, limited growth of the condyle in a posterior direction, together with extensive alveolar growth, would result in a posterior total rotation.

Total rotation and structural superimposition are important because they relate to the internal

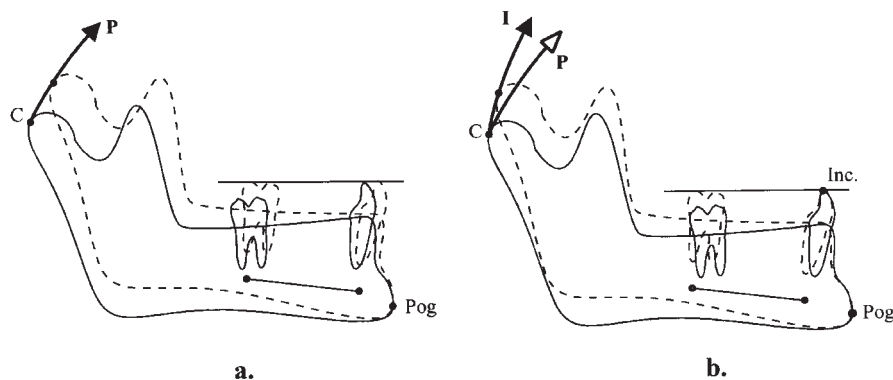


Figure 4 (a) Growth of the condyle along the circular path P, having Pog as its centre, will not increase mandibular length as measured from condylion to pogonion. Mandibular shape could remain unchanged by appropriate periosteal remodelling, which is evidenced only by superimposing on metallic implants (redrawn from Dibbets, 1985). (b) Growth of the condyle along the circular path I, having the lower incisor tip as its centre, will not affect the anteroposterior occlusal relationship because the distance of the incisor to the fossa remains constant. Mandibular length as measured from the condyle to Pogonion will, however, increase because the condyle now grows outside the circular path P, having Pog as its centre. Mandibles are superimposed on metallic implants.

stable structures of the mandible. As condylar growth proceeds, the old condyle is relocated and becomes incorporated into the internal ramus and corpus of the mandible. Condylar growth is, therefore, visualized only by structural superimposition. This has been demonstrated by Dibbets (1985), who has shown that, in principle, there could be active condylar growth, but without any change in mandibular size and shape, due to compensating periosteal remodelling (Figure 4a). Similarly, it can be demonstrated that mandibular size can increase, but without contributing to any change in anteroposterior occlusal relationship (Figure 4b). A more general result is that the same overall anatomical change could be produced by completely different underlying skeletal and dental changes (Figure 5). The last point clearly illustrates the failure of conventional cephalometric measurements, that rely exclusively on surface landmarks, to reveal and differentiate the underlying biological growth processes. The only indication that different growth processes have taken place between the final mandibles is the amount of total rotation.

Total rotation is measured in step 4 of the proposed method and is used in a subsequent step in order to arrive at the direction of condylar growth.

Step 5 is similar to step 2. The initial lower molar is transferred to the final radiograph after structural superimposition of the mandibles. This would be the final position of the lower molar if no dental movement within the mandible had occurred. One could assume that the relocation of the lower molar from the initial to the L_A position is due to skeletal growth (relocation of the fossa and growth of the condyle) and the movement of the molar from position L_A to the final position L_F is dental in nature.

However, at this point the effect of mandibular rotation must be considered. If no total rotation has occurred, then the magnitude and direction of the skeletal and dental components just described is valid. If, however, rotation has occurred, then the results are misleading. The distance between the initial position of the lower molar and position L_A is not equal to skeletal growth because there has not been a *parallel* translation of the internal mandibular structures. In order to achieve the same orientation between the initial and final mandibles the final mandible needs to be derotated by an amount equal, but opposite to the measured total rotation. This is accomplished in step 6. The measurements in step 7 can now be explained as follows: *Mandibular Skeletal* is the combined

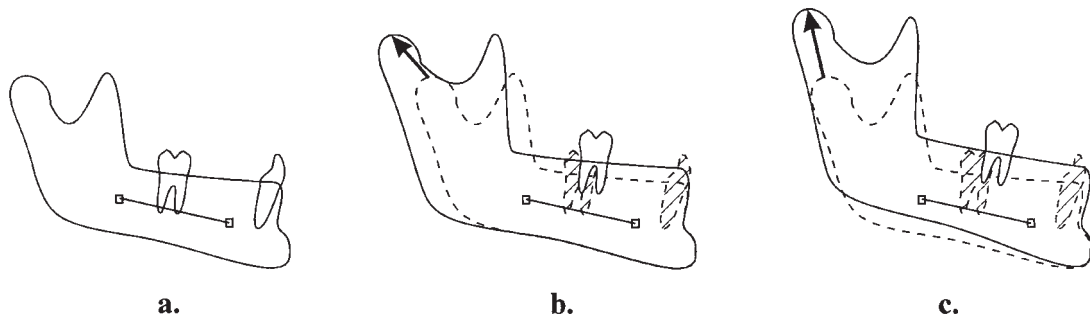


Figure 5 How a mandible can grow in two different ways, yet remain the same. (a) Pre-treatment tracing. Metallic implants are shown with small squares in the body of the mandible. (b) Growth of the condyle in an upward and backward direction. The lower molar moved anteriorly and occlusally. (c) Alternative growth pattern. The condyle grew in a more vertical direction and to a larger extent. Dental movement was also more pronounced. However, the final size and shape of the mandible is identical to (b) due to appropriate periosteal remodelling (the reader can confirm this by superimposing the outlines of the final mandibles). No conventional cephalometric measurement relying on surface landmarks could differentiate between these two growth patterns.

measure of fossa repositioning and condylar growth. The lower molar would be relocated by this amount if no dental movement had occurred (e.g. ankylosis) and no rotation had taken place, i.e. if vertical growth of the maxilla were equal to vertical growth at the condyle and the mandible had grown downward and forward in a parallel fashion. *Mandibular Dental* shows the dental movement of the lower molar. Vector addition of *Mandibular Skeletal* and *Mandibular Dental* shows the position that the lower molar would occupy if no rotation had occurred. The vector *Mandibular Rotation* shows any additional molar movement due to mandibular rotation, which may result from a discrepancy between vertical alveolar and condylar growth.

It is again stressed that these vectors do not represent *actual* intermediary positions in the relocation of the lower molar during growth. They only show the independent *effect* of each of the three most important growth processes on the total molar movement.

A diagrammatic presentation of the above variables can be constructed to obtain a visual impression of the changes that have taken place (Figure 3). The final occlusal plane is used as the horizontal reference axis. Vectors *Mandibular Skeletal* and *Maxillary Skeletal* are drawn so that

they start from the same position and the other vectors are connected end-to-end to these. In this way, the horizontal distance between the ends of vectors *Mandibular Rotation* and *Maxillary Dental* represents the change in molar occlusal relationship. This distance can be calculated from the x-component of the vectors and should equal the change in molar occlusion as recorded from the dental casts, allowing for radiographic enlargement.

To demonstrate the use of the method, it was applied to a sample of 21 cases presented by Björk and Skieller (1972). These cases were followed over a 5- or 6-year period and have been extensively documented using metallic implants. Cephalometric tracings have been published at half size for three time points: A, pre-pubertal; B, pubertal; and C, post-pubertal. For the purposes of this paper, tracings A and C were used. They were enlarged by a factor of 2 and measured using a slightly modified method to the one outlined above, as they were already superimposed on the cranial base.

Results

Descriptive statistics of the proposed measurements for the 21 cases are shown in Table 1.

Table 1 Descriptive statistics for the five proposed measurements. Each measurement can be projected on the occlusal plane and on a perpendicular to the occlusal plane, and thus be resolved into an X and Y component. The X component is positive if the final position is mesial to the initial position. The Y component is positive if the final position is caudal to the initial position. The mandibular rotation vector was designated negative in cases of backward mandibular total rotation.

	<i>Mandibular Skeletal</i>			<i>Mandibular Dental</i>			<i>Mandibular Rotation</i>			<i>Maxillary Skeletal</i>			<i>Maxillary Dental</i>		
	Length	X	Y	Length	X	Y	Length	X	Y	Length	X	Y	Length	X	Y
Mean	19.01	1.91	-18.13	5.40	2.52	4.27	7.09	4.26	5.60	6.04	4.92	-3.28	6.07	2.58	-5.27
St.Dev.	4.75	5.09	5.22	1.39	2.04	1.61	5.24	3.53	3.98	1.96	1.76	1.54	2.09	1.59	2.11
Median	19.82	3.18	-19.36	5.50	2.56	4.54	7.35	3.61	6.28	5.60	4.75	-2.72	6.45	2.44	-5.57
Centile 5%	10.58	-5.77	-24.65	3.15	-0.20	1.28	-2.62	-1.26	-2.30	3.54	1.98	-5.70	3.12	0.29	-8.75
Centile 95%	26.76	8.16	-8.40	7.22	5.10	5.94	12.88	9.43	10.81	8.85	7.49	-1.22	8.79	4.94	-2.45

Cases 1 and 9 did not have maxillary metallic implants so the descriptive statistics of the maxillary variables were calculated on the remaining 19 subjects. Variables *Mandibular Skeletal* and *Mandibular Rotation* showed the highest variability of all measurements. Diagrammatic presentations of the measurements for each of the 21 cases are shown in Figure 6. The graphs are arranged according to the angle that the *Mandibular Skeletal* vector extends to the occlusal plane.

The *Mandibular Skeletal* measurement mainly represents the amount and direction of condylar growth. In cases where no appreciable fossa relocation relative to the anterior cranial base has occurred (e.g. Case 5), the length of this vector is equal to the condylar growth intensity. In the more general case, *Mandibular Skeletal* shows the combined effect of condylar growth, fossa repositioning and condylar changes within the fossa on the total displacement of the mandible. Because fossa changes are usually small compared to the much greater amount of condylar growth, this variable can be used to give an estimation of condylar growth intensity and direction. The correlation coefficient between *Mandibular Skeletal*, as measured here, and *condylar growth intensity*, as measured and reported by Björk and Skieller (1972), was calculated at $r = 0.93$ ($P < 0.001$). Regression analysis between the two variables shows that condylar growth can be deduced from *Mandibular Skeletal* with a

95 per cent prediction interval of 3 mm. The correlation coefficient between the angle that the *Mandibular Skeletal* vector extends relative to the occlusal plane and *condylar growth direction*, as measured and reported by Björk and Skieller (1972), was calculated at $r = 0.94$ ($P < 0.001$).

Observation of Figure 6 shows that the first five cases exhibited a posteriorly directed skeletal translation vector, a result of distal migration of the fossa and anterior growth of the condyle. These growth changes would result in a backward mandibular displacement, were it not for the large anterior corpus rotation (*Mandibular Rotation* vector), which reversed the trend and contributed to the usual overall downward and forward mandibular repositioning. It is interesting to note that these five cases were all Class II and that they all showed a deterioration of molar occlusion during growth (Björk and Skieller, 1972). In contrast, most of the Class III cases were observed to have an anteriorly directed mandibular skeletal vector, but also worsening of the Class III molar relationship. The correlation coefficient between the direction of *Mandibular Skeletal* and the change in molar occlusion for the 19 cases that showed anterior total rotation was calculated at $r = 0.67$ ($P < 0.01$).

Cases 2 and 4 are those where posterior total rotation was noted. These cases showed the most anteriorly directed *Mandibular Skeletal* vector. With reference to Figure 6, it appears that the

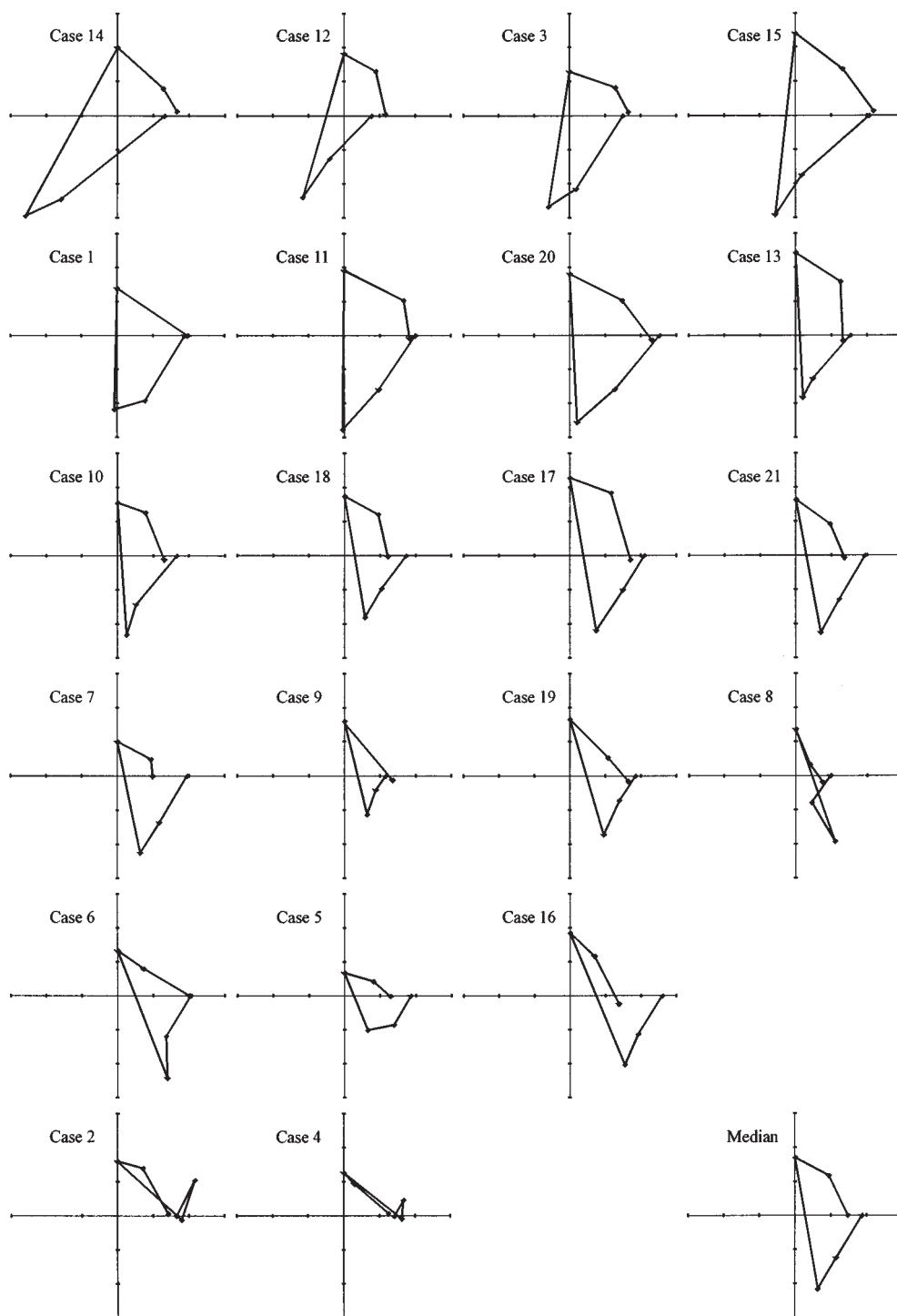


Figure 6 Graphical presentation of the measurements for the 21 cases presented by Björk and Skieller (1972). Axes are marked at 5-mm intervals.

extreme anterior mandibular translation and the eruption of the lower molar have caused the end of vector *Mandibular Dental* to lie above the occlusal plane, leaving no 'room' for forward rotation. In these cases backward rotation seems inevitable.

The *Mandibular Rotation* measurement is directly related to total rotation of the mandible. The correlation coefficient between *Mandibular Rotation* and *total rotation* was calculated and found high ($r = 0.99$, $P < 0.001$), as would be expected from the way this variable was derived.

Discussion

Most of the measurement methods that appear in the literature measure the combined effect of condylar growth, mandibular rotation and periosteal remodelling on the anatomical change of the mandible. In contrast, the proposed method appears to differentiate between the effect of each growth process and to measure them independently. This differentiation is made possible by the use of structural superimpositioning methods and derotation of the mandible.

Two points must be noted. First, regional superimposition of the maxilla is rather problematic and not as accurate as that of the mandible. Stable anatomical landmarks in the maxilla have been sought but no consensus currently exists (Björk and Skieller, 1977; Nielsen, 1989; Doppel *et al.*, 1994). Superimposition on the anterior and posterior surface of the zygomatic process is recommended (Doppel *et al.*, 1994), although in cases of uncertain superimposition, it may be best to combine the maxillary and the upper molar movements in a single measurement describing the combined skeletal and dental changes, even if loss of information occurs (as occurred in Cases 1 and 9 in Figure 6, where maxillary implants were not present).

The second point concerns the mandible. The change in position of the internal mandibular structures as measured in this investigation (*Mandibular Skeletal* measurement) cannot differentiate condylar growth from fossa remodelling or changes in condyle position within the fossa. Such differentiation would require detailed tracing of the condyle, which is difficult on

standard cephalograms. This is, however, also an advantage, because there is no need to use questionable points, such as articulare, or those prone to location errors, such as condylion. The close correlations between the *Mandibular Skeletal* measurement and the intensity and direction of condylar growth may allow us to use this measurement as a reliable indicator of condylar growth.

Mandibular repositioning due to growth was measured after rotating the mandible in an opposite direction, but by an equal amount to the observed total rotation. This derotation was considered essential, in order to separate the growth at the condyle from the vertical growth of the alveolar processes, as these two may be biologically independent. The measurement of mandibular growth direction is, in this way, not confounded by dental changes, otherwise, a patient exhibiting little vertical alveolar growth would seem to have a more horizontal mandibular growth pattern than a patient with large vertical alveolar growth. Derotation of the mandible was accomplished by using the centre of the condyle as the rotation centre. Björk and Skieller (1983) suggested that it is the matrix and not the corpus that rotates with the condyles as the rotation centre. This observation is not contradicted here. The change in position between the initial and final mandibular corpus can be described either as a pure rotational movement or as a combination of translation and rotation. Using a pure rotational movement would result in a single rotation centre that could be positioned at any point, even outside the mandible. In contrast, a combination of translation and rotation allows us to choose the rotation fulcrum at will. Using the condyle as the rotation centre has the advantage that the translation vector is directly related to condylar growth. If no relocation of the fossa occurs during growth, the *Mandibular Skeletal* measurement will be equal to the amount of condylar growth, otherwise it will be equal to the vector sum of condylar growth and fossa repositioning.

Derotation of the maxilla, in order to separate the translational from the rotational component of growth, was not attempted. The main reason was that the maxilla is not attached to the cranium

by an articulation that permits rotational adjustments. Although the amount of maxillary rotation could be measured, no anatomical landmark could justifiably be used as a rotation centre. It was thus decided to express the total effect of maxillary skeletal growth on the position of the upper molar in a single measurement.

It is convenient for measurements to be expressed along the direction of the malocclusion, in order to facilitate the assessment of each measurement's contribution to total correction. The purpose of the proposed method is to analyse the change in anteroposterior occlusal relationship. For this reason the occlusal plane was chosen as the reference axis, as this is the plane along which dental correction is achieved.

Regional superimposition has been used in previous studies but its widespread acceptance has probably been hindered by the difficulty of the method. However, this has now been reduced or eliminated by computer systems, while accuracy has increased (Halazonetis, 1994).

Williams and Melsen (1982a,b) have attempted to differentiate between sutural growth of the maxilla, displacement of the mandible, and dental movements, using metallic implants and the occlusal plane as a reference line. Their method has not gained acceptance, probably because it was based on measurements from the implants, thereby not being easily adaptable to structural superimpositioning. Baumrind and co-workers have developed a method similar in many respects to the one proposed here (Baumrind *et al.*, 1983a,b; Ben-Bassat *et al.*, 1986), but without using a structural method for superimposition and without considering total rotation. This method, too, has not been followed by others, although interesting results were obtained from the study of various treatment groups. Perhaps, the amount of detail presented and the lack of a summary graphical presentation of the overall changes that were observed, were discouraging. In contrast, more easily comprehensible methods, such as simple anteroposterior analyses along the occlusal plane, have proved more enduring (Pancherz, 1982; Johnston, 1986; Livieratos, 1993; Harris *et al.*, 1994), although vertical changes are completely disregarded or insufficiently represented.

The main application of the method presented here is to elucidate the mode of action of treatment modalities by differentiating between local tooth movement, movement of the tooth-bearing maxillae and movement due to rotation. These are biological movements of specific dento-facial units, which are considered to respond differently to various treatments. It is hoped that this paper will stimulate scientific thought and discussion, so that a standardized measurement system is developed that is widely accepted, and applied in growth and treatment assessment studies.

Conclusions

The proposed method offers several advantages:

1. It is easy and fast because only one tracing of natural reference structures is involved and all measurements are delegated to the computer.
2. Errors associated with landmark identification are minimal because fiducial points are mostly used.
3. It is comprehensive, including measurements related to amount and direction of condylar growth, amount and direction of mandibular total rotation, maxillary growth in the vertical and anteroposterior direction, and dental movements of the molars vertically and anteroposteriorly.
4. It is compact, as all the information is included in the size and orientation of five vectors.
5. The contribution of each skeletal and dental component to the change in molar relationship (Class II or III correction) can be assessed.
6. A graphical representation of the measurements can be drawn to give a visual impression of growth and treatment changes.

Address for correspondence

D. Halazonetis
6 Menandrou Street
Kifisia 145 61
Greece

References

- Baumrind S, Korn E L, Isaacson R J, West E E, Molthen R 1983a Quantitative analysis of the orthodontic and orthopedic effects of maxillary traction. *American Journal of Orthodontics* 84: 384–398
- Baumrind S, Korn E L, Isaacson R J, West E E, Molthen R 1983b Superimpositional assessment of treatment-associated changes in the temporomandibular joint and the mandibular symphysis. *American Journal of Orthodontics* 84: 443–465
- Baumrind S, Korn E L, Ben-Bassat Y, West E E 1987 Quantitation of maxillary remodeling. 2. Masking of remodeling effects when an 'anatomical' method of superimposition is used in the absence of metallic implants. *American Journal of Orthodontics and Dentofacial Orthopedics* 91: 463–474
- Ben-Bassat Y, Baumrind S, Korn E L 1986 Mandibular molar displacement secondary to the use of forces to retract the maxilla. *American Journal of Orthodontics* 89: 1–12
- Björk A, Skieller V 1972 Facial development and tooth eruption. An implant study at the age of puberty. *American Journal of Orthodontics* 62: 339–383
- Björk A, Skieller V 1977 Growth of the maxilla in three dimensions as revealed radiographically by the implant method. *British Journal of Orthodontics* 4: 53–64
- Björk A, Skieller V 1983 Normal and abnormal growth of the mandible. A synthesis of longitudinal cephalometric implant studies over a period of 25 years. *European Journal of Orthodontics* 5: 1–46
- Dibbets J M H 1985 The puzzle of growth rotation. *American Journal of Orthodontics* 87: 473–480
- Doppel D M, Damon W M, Joondeph D R, Little R M 1994 An investigation of maxillary superimposition techniques using metallic implants. *American Journal of Orthodontics and Dentofacial Orthopedics* 105: 161–168
- Enlow D H 1982 Handbook of facial growth. W B Saunders Company, Philadelphia
- Halazonetis D J 1994 Computer-assisted cephalometric analysis. *American Journal of Orthodontics and Dentofacial Orthopedics* 105: 517–521
- Harris E F, Vaden J L, Dunn K L, Behrents R G 1994 Effects of patient age on the postorthodontic stability in Class II, division 1 malocclusions. *American Journal of Orthodontics and Dentofacial Orthopedics* 105: 25–34
- Johnston L E Jr 1986 A comparative analysis of Class II treatments. In: McNamara J A Jr, Carlson D S, Vig P S, Ribbens K A (eds) *Science and clinical judgement in orthodontics*. Monograph No. 18, Craniofacial Growth Series. Center for Human Growth and Development, The University of Michigan, Ann Arbor, pp. 103–148
- Livieratos F A 1993 Class II treatment: A comparison of one- and two-stage non-extraction alternatives. Master's Thesis, University of Michigan, Ann Arbor
- Nielsen I L 1989 Maxillary superimposition: a comparison of three methods for cephalometric evaluation of growth and treatment change. *American Journal of Orthodontics and Dentofacial Orthopedics* 95: 422–431
- Pancherz H 1982 The mechanism of Class II correction in Herbst appliance treatment. A cephalometric investigation. *American Journal of Orthodontics* 82: 104–113
- Williams S, Melsen B 1982a Condylar development and mandibular rotation and displacement during activator treatment. An implant study. *American Journal of Orthodontics* 81: 322–326
- Williams S, Melsen B 1982b The interplay between sagittal and vertical growth factors. An implant study of activator treatment. *American Journal of Orthodontics* 81: 327–332

Appendix—detailed description of the method

The method consists of two main parts, each of which require several steps. The first part concerns the tracing of the radiographs and the digitization of the relevant points and the second involves measurement of the variables by computer.

Part A

Step 1. The first lateral cephalogram (initial) is traced on acetate paper. The purpose of this is to construct five templates, one each of the anterior cranial base, the maxilla, the mandible, and the upper and lower first molars. For this purpose, only internal structures that are considered stable during growth need to be traced (Björk and Skieller, 1977, 1983). Such structures include the anterior part of sella turcica, the cribriform plate of the ethmoid, the zygomatic process of the maxilla, the mandibular canal, the labial cortical plate of the symphysis, any developing tooth buds before the formation of their root, and any conspicuous trabecular bone patterns.

Step 2. Six fiducial points are marked on the tracing. The exact location of four of these points is not significant. To avoid confusion, it is convenient to place them at some distance from the drawings of Step 1 (Figure A1).

1. Two points are marked for the mandible (MD1, MD2). It is recommended to place these outside the mandibular outline, near gonion and gnathion.
2. Two points are marked for the maxilla (MX1, MX2), above the anterior and posterior nasal spines.

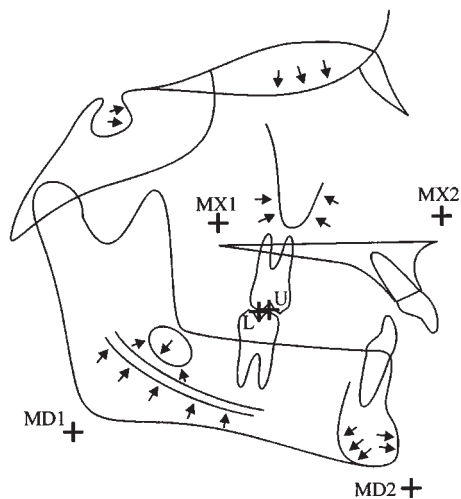


Figure A1 Tracing of the initial cephalogram. Small arrows show areas that are used for structural superimposition. Only these areas and the first molars need to be traced. The six fiducial points are marked with a cross. (The drawings of this and subsequent figures are not based on a particular patient but are for demonstration purposes.)

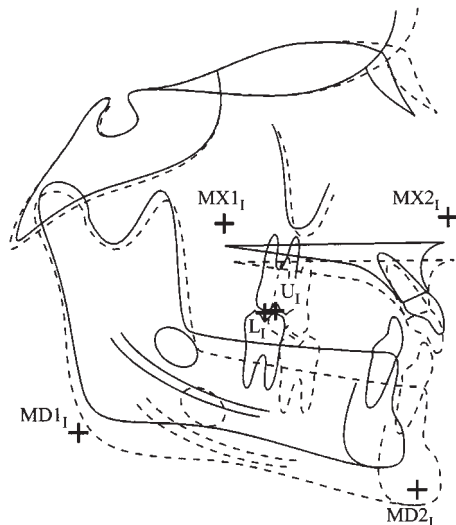


Figure A2 Tracing of first radiograph (continuous line) positioned on second radiograph (broken line) and superimposed on internal structures of the anterior cranial base. The second radiograph is fixed on the digitizer tablet and all fiducial points are digitized.

3. One point is marked at the middle of the occlusal surface of the upper first molar (U) and one point at the middle of the occlusal surface of the lower first molar (L). The position of these two fiducial points should not be changed.

Step 3. The second radiograph is placed and secured on the surface of the digitizer. The traced acetate paper from Step 2 is laid on the film and the following superimpositions and digitizations are sequentially performed.

1. Cranial base superimposition (Figure A2). The tracing is positioned so that the internal reference structures of the anterior cranial base are superimposed (Björk and Skieller, 1983). Then all six fiducial points of the tracing are digitized. These represent the initial locations of the fiducial points and will be denoted with the subscript I (MD1_I, MD2_I, MX1_I, MX2_I, U_I, L_I).
2. Mandibular superimposition (Figure A3). The tracing is repositioned so that the internal structures of the mandible are superimposed

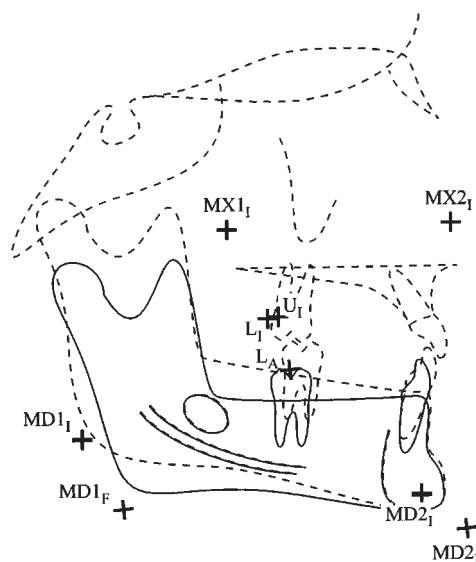


Figure A3 Tracing repositioned to superimpose on stable structures of the mandible (only part of the tracing is shown for clarity). Points MD1, MD2 and L are digitized and noted as MD1_F, MD2_F and L_A.

(Björk and Skieller, 1983). Points MD1, MD2, and L are digitized again. Points MD1 and MD2 now represent the final position of

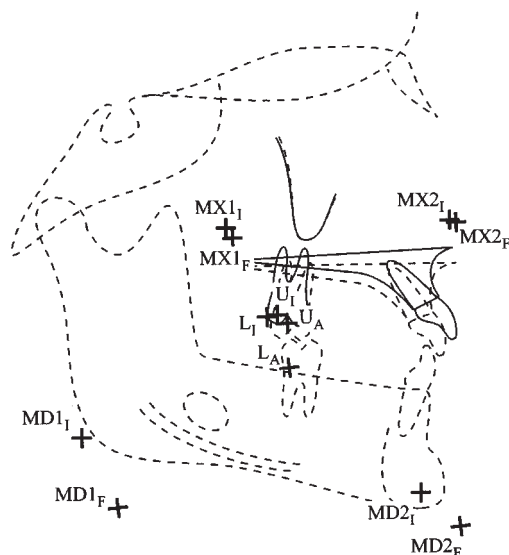


Figure A4 Tracing repositioned and superimposed on stable structures of the maxilla (again, only the relevant part of tracing is shown). Points MX1, MX2 and U are digitized and noted as MX1_F, MX2_F and U_A.

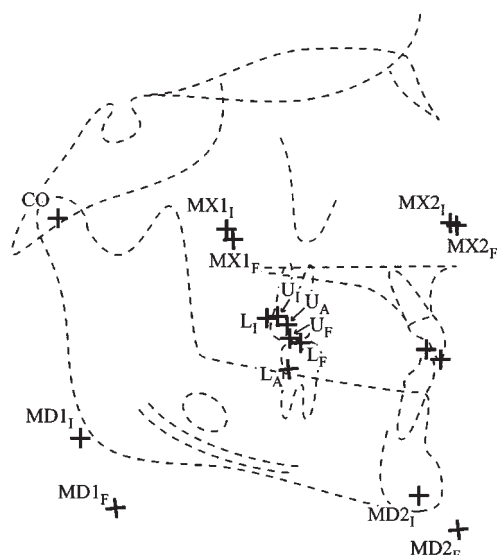


Figure A5 All digitized points. Points U_F and L_F have been digitized after superimposing on the upper and lower molars. Point CO is the centre of the condyle. The incisal edges of the upper and lower central incisors are used to define the occlusal plane.

the mandible and will be denoted with the subscript F (MD1_F, MD2_F). Point L would be the final position of the lower molar if no dental movement of the molar relative to the internal structures of the mandible had occurred. It will be denoted by the subscript A (ankylosed, L_A).

3. Maxillary superimposition (Figure A4). The tracing is repositioned to superimpose on the internal structures of the maxilla (see Discussion). Points MX1, MX2, and U are digitized. Points MX1 and MX2 represent the final position of the maxilla, and will be denoted with the subscript F (MX1_F, MX2_F), while point U is the position that the upper molar would have had if no dental movement had occurred. The subscript A (ankylosed) will be used (U_A).
4. Upper molar. The tracing is positioned so that the upper molars are superimposed and point U is digitized. This is the final position (U_F).
5. Lower molar. Similarly, after superimposing on the lower molar, point L is digitized (L_F).
6. The incisal edges of the upper and lower central incisors as well as the centre of the

mandibular condyle (point CO) are also digitized. No superimposition is involved, the landmarks being taken directly from the radiograph. (Figure A5).

Part B

In the second part of the method a computer program (Halazonetis, 1994) performs the following steps in order to produce the required measurements.

Step 1. A point midway between the incisal edges of the upper and lower incisors and a point midway between points U_F and L_F are located. These points are used to define the occlusal plane.

Step 2. Total mandibular rotation is measured as the angle between lines MD1_I-MD2_I and MD1_F-MD2_F.

Step 3. Points MD1_F, MD2_F are duplicated and given the subscript T (for translation): MD1_T, MD2_T. Point L_F is duplicated and given the subscript R (for rotation): L_R.

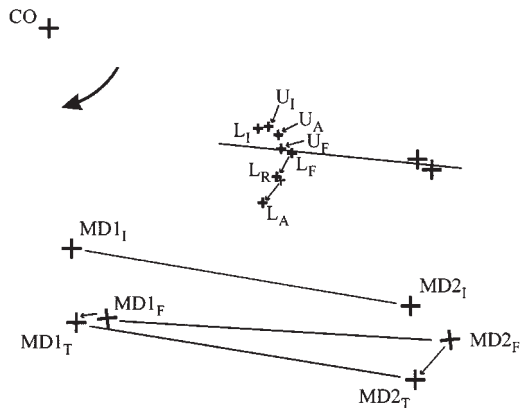


Figure A6 Diagrammatic presentation of the derotation carried out by computer. Points MD1_F, MD2_F, and L_F are duplicated, renamed as MD1_T, MD2_T, and L_R, and then rotated, together with point L_A, by an angle equal, but opposite to the measured total rotation. Point CO is used as the rotation centre. The line joining the two mandibular fiducial points (MD1_T, MD2_T) now becomes parallel to the initial line (MD1_I, MD2_I).

Step 4. (Figure A6) Using point CO as a centre, points MD1_T, MD2_T, L_A and L_R are rotated by an angle equal, but opposite, to the measured total mandibular rotation. This step effectively reverses any mandibular rotation that has occurred between the two radiographs. Points MD1_T and MD2_T now represent the position the mandible would have if it had grown by pure

translation with no rotation. Point L_A represents the position of the lower molar after this pure translatory growth if no dental movement had occurred. Point L_R is the position of the lower molar taking into account any additional dental movement.

Step 5. The following vectors are measured using the occlusal plane as the reference axis. Each vector is measured by its length, the distance between the end-points that define it. It can also be projected on the occlusal plane and on a perpendicular to the occlusal plane and, therefore, has an X and a Y component:

1. *Mandibular Skeletal*: the vector between points L_I and L_A. This measurement is equal to that obtained by using points MD1_I and MD1_T, or MD2_I and MD2_T.
2. *Mandibular Dental*: the vector between points L_A and L_R.
3. *Mandibular Rotation*: the vector between points L_R and L_F.
4. *Maxillary Skeletal*: the vector between points U_I and U_A.
5. *Maxillary Dental*: the vector between points U_A and U_F.

Step 6. (Figure 3) A diagrammatic presentation of the above variables can be constructed to obtain a visual impression of the changes that have taken place.